

Examples of

Micro-surgery to the vocal folds

By Dr David Lau

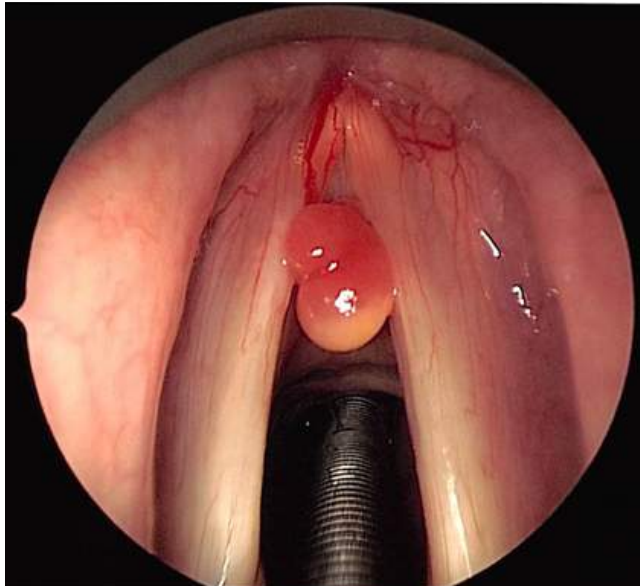
Specialist in Ear, Nose & Throat Surgery

Gleneagles Hospital, Singapore

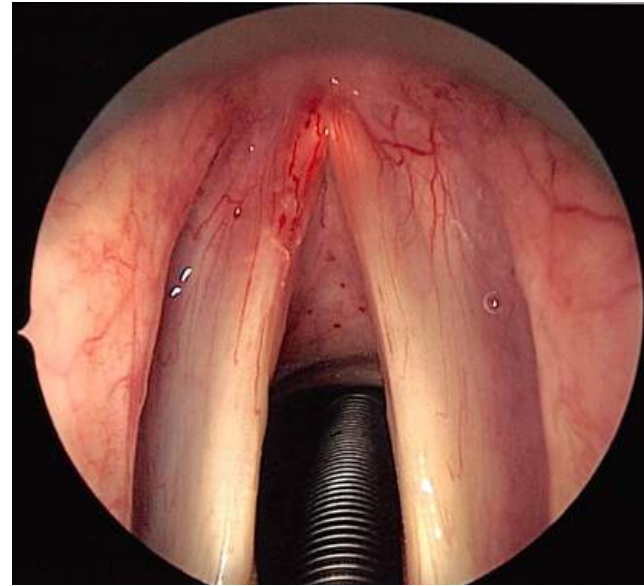


David Lau ENT Centre

Vocal polyp



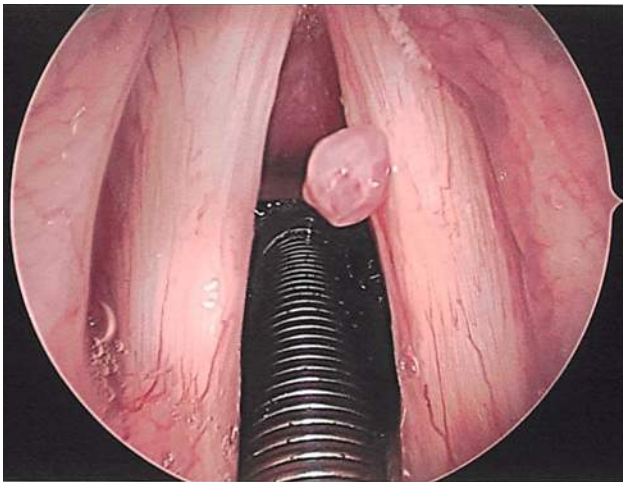
Before



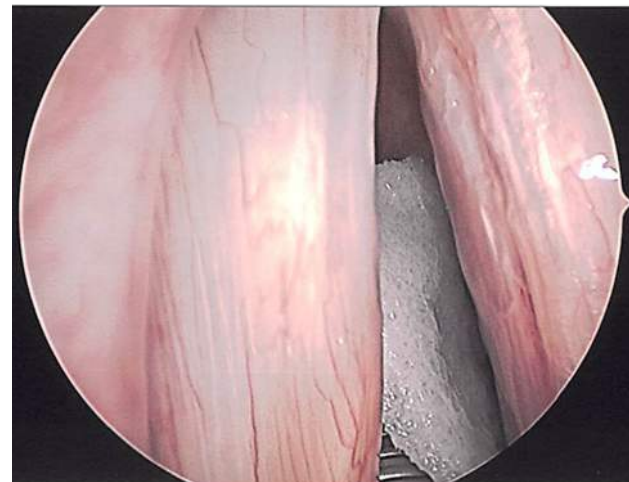
After

Minimally invasive surgery is used to remove the polyp. The blood vessel supplying the polyp is also sealed

Vocal polyp



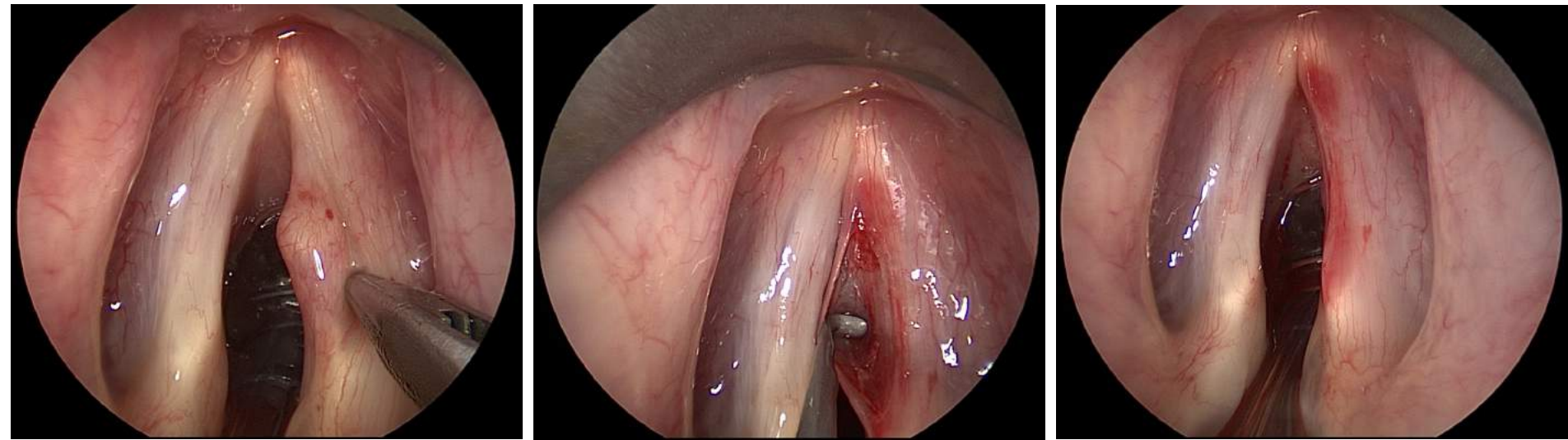
Before



After

Another example of surgery to remove a vocal polyp. Micro-surgical laser techniques minimize injury to the vocal fold

Vocal cyst



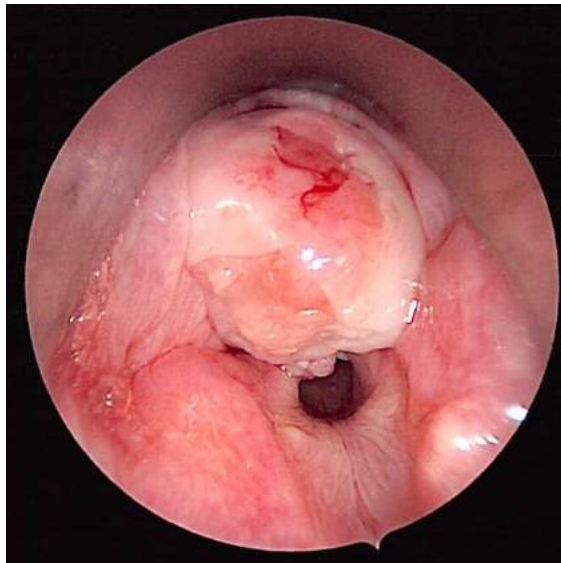
Before

Flap elevation

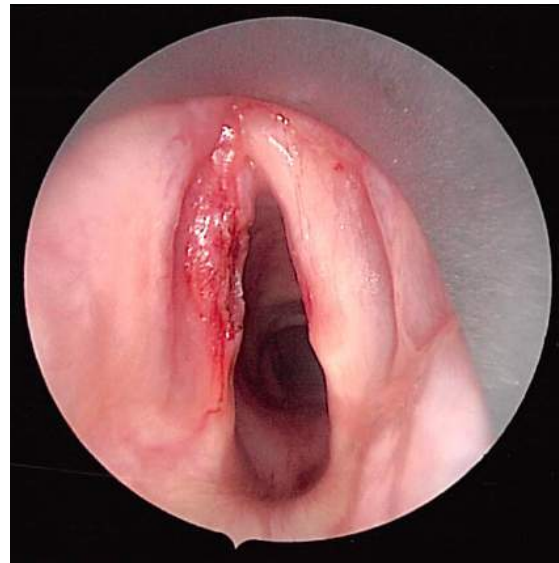
After

Vocal cysts are removed using a different micro-surgical technique to lift a flap of vocal fold lining to reach the cyst. After removal the flap is replaced.

Large polyp blocking the airway



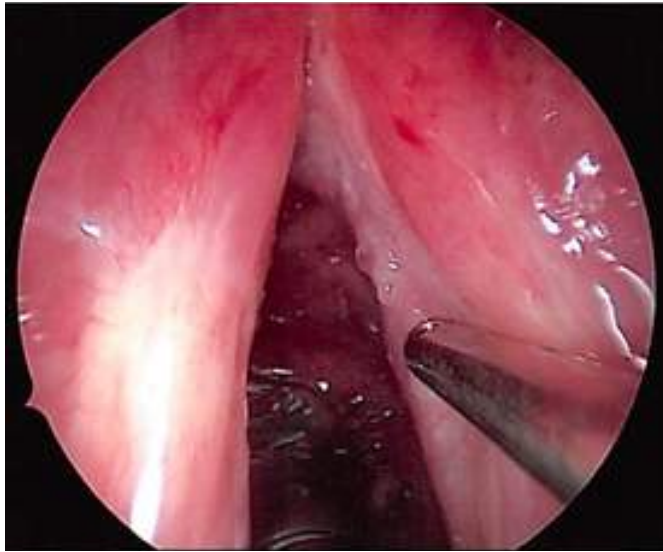
Before



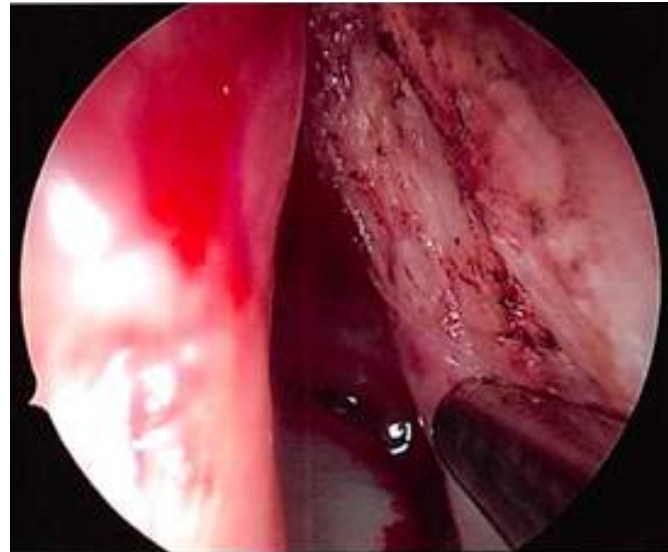
After

This large polyp was obstructing the breathing passage. It was removed with a laser.

Vocal fold cancer



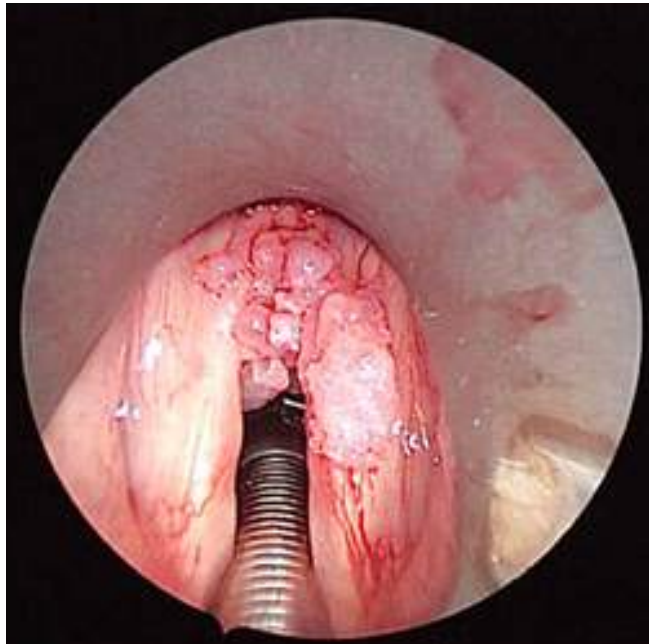
Before



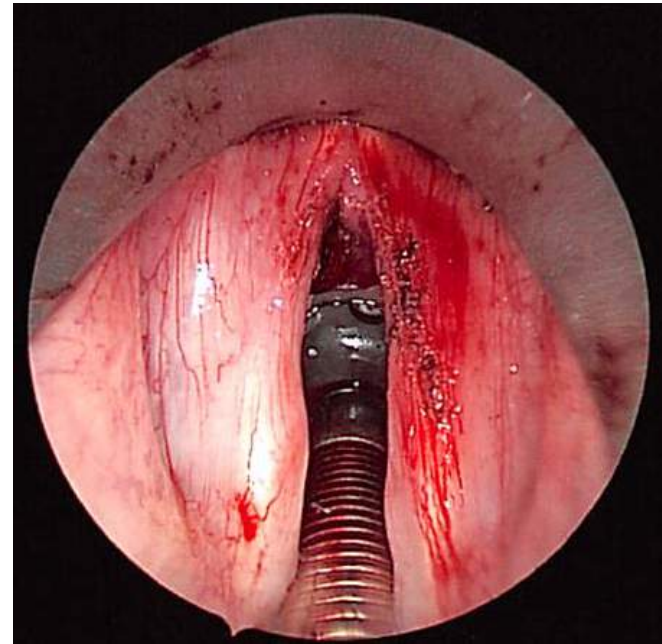
After

A laser was used to remove the cancer from the right vocal fold while preserving vocal function and the patient's voice

Respiratory papillomas



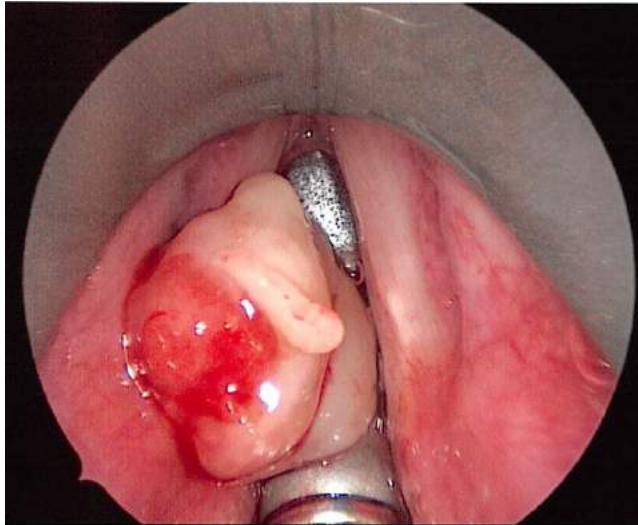
Before



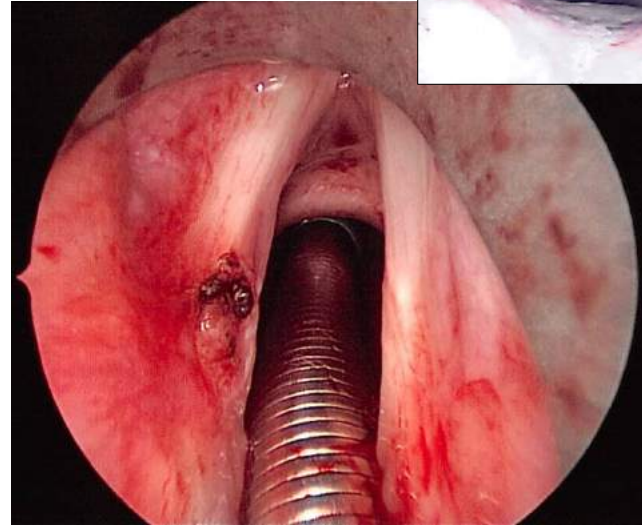
After

Careful microsurgical technique leaves a small bridge of tissue between the vocal folds to prevent scar tissue forming here which could cause persistent hoarseness

Contact granuloma

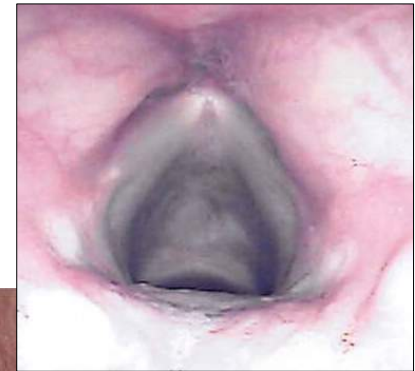

Before



After

(inset after 1 year)



Contact granulomas are known to have high recurrence rates. Meticulous removal and post-operative regimen can lead to successful outcome